

Universal Adhesives: have it your way

Outstanding bond strength required for all indications

By Dr Ron Kaminer



Dr Ron Kaminer

Since 1955, when Dr. Michael Buonocore, challenged dentistry with his primitive yet innovative form of bonding, materials and techniques have evolved dramatically. Yet despite the improvement in materials and techniques, when surveying a recent group of dentists, I realized that the group still uses a variety of techniques and materials to achieve a similar outcome. Some still use phosphoric acid and then an adhesive, some use self-etch primer and an adhesive and some use a single bottle, self-etch primer and bond. One of the negative characteristics with self-etch primer and bond as compared to a phosphoric acid etch and bond system is adequate but decreased bond strengths. It is for this reason that many still like to use phosphoric acid prior to using a one bottle self-etch primer and bond (for improved bond strengths). This last statement is true for enamel but if one were to use 37% phosphoric acid on dentin prior to a self-etch primer and bond, a decrease in bond strengths and potential sensitivity often encountered. This occurs by the phosphoric acid removing more dentin mineral that can be filled by self-adhesive monomers.

A new generation of bonding materials called the universal adhesives have been created so that dentists have the option of total-etch or self-etch with no concern of sensitivity and decreased bond strengths when used in conjunction with phosphoric acid on dentin. One such product, Futurabond U (VOCO), offers simplicity of use with outstanding bond strengths. Futurabond U differs from its predecessor Futurabond DC (VOCO) in a number of characteristics. Futurabond U has a higher pH value than conventional self-etching systems like Futurabond DC. This higher pH value will not allow for over etching of the already etched dentin in the total-etch technique. Futurabond U has a new surfactant which improves its wettability leading to lower surface tension and improved bond strengths. Finally, the monomer chemistry is different than its predecessor thus enhancing the effect of the new acid.

Futurabond U doesn't differ from its predecessor in one of its most useful traits: the packaging. The

unique and innovative foil packaging of Futurabond U in the *SingleDose* blister really separates it from all other adhesives on the market. The foil packaging consists of two compartments each with its own unique chemistry. By pressing on a certain spot in the packaging the material from one side shoots internally to the other side, allowing for an instantaneous fresh mix of the chemistry. In the self-etching technique, a microbrush is now used to penetrate the foil into the material and then consequently brush it onto the tooth. This eliminates any evaporation of material that can occur from a bottle being left open or material being dispensed onto a dappen dish. In the total-etch technique a 37% phosphoric acid is used on dentin and enamel for ten seconds, rinsed off followed by the application of Futurabond U. The material is brushed on for twenty seconds, air dried for five seconds and light cured for ten seconds. At this point the tooth is ready to accept the restoration.

Due to its low film thickness Futurabond U is ideal for indirect as well as direct restorations. Its chemistry allows it also to be used with any dual cure or self-cure materials, eliminating any potential material incompatibility issues bond strengths in these instances still remain quite high, a feature not often seen with other systems. Futurabond U also bonds to zirconia, metals, aluminum oxide and silicate ceramics without the need for any other primers. It is also quite strong with bond strengths over thirty MPa to enamel and dentin.

The following two clinical examples will illustrate how Futurabond U can be used clinically to achieve outstanding results.

Case 1:

As previously stated Futurabond U can be used in the self-etch mode or with phosphoric acid in the selective-etch or total-etch mode. In this case, when bonding to an incisal edge, we elected to use phosphoric acid first to improve bond strengths of the composite. Our pre-op photo shows a chip on the incisal edge of tooth 21 (figure 1). A 37% phosphoric acid (Ultra etch, Ultradent Corp.) was used on the

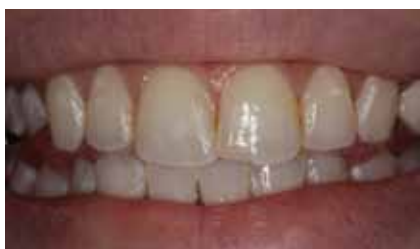

Figure 01: A chip on the incisal edge of tooth 21.

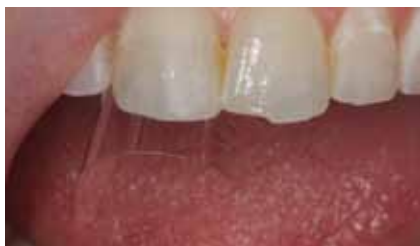

Figure 03: Futurabond U on the tooth after curing.

enamel for ten seconds (figure 2). After thoroughly rinsing off the etchant, a mylar strip was placed between tooth 11 and tooth 21, and Futurabond U was brushed on the enamel for twenty seconds and air dried for five seconds. Futurabond U was then light cured for ten seconds. One of the nice things about Futurabond U is that you can see it on the tooth after curing (figure 3). This reinforces the fact that you have adhesive in place before placing the direct restorative. The final restoration is placed (GrandioSO, shade A1, VOCO), light cured, finished and polished (figure 4).

Case 2:

Incipient decay can be treated conservatively with tunnel preparations, in order to avoid removing unnecessary tooth structure. Radiographic examination in this case reveals early onset decay in and around the contact area between the second bicuspid 15 and the molar 16 (figure 5). Clinical exam reveals no occlusal break from decay (figure 6). A tunnel preparation approach was chosen to access and remove the decay on both teeth (figure 7). Futurabond U was used here in the self-etch mode according to manufacturer's instructions (figure 8). After light curing, GrandioSO Flow (VOCO), a highly filled esthetic flowable composite, was used to fill the cavity (figures 9 and 10). This material while strong is also very esthetic as evidenced by the natural appearance and blending of the restoration with the existing tooth structure.

Universal adhesives such as Futurabond U are the newest advances in dentistry as it relates to the bonding process. They eliminate the need for multiple adhesive systems and allow you

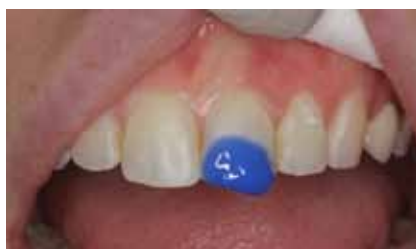

Figure 02: A 37% phosphoric acid was used on the enamel for ten seconds.

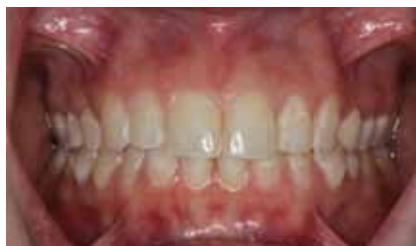

Figure 04: The final restoration is placed, light cured, finished and polished.

to bond restorations in any manner that you like. In other words they allow you to "Have it Your Way". ♦

Contact: Dr Ron Kaminer
 1315a Broadway
 Hewlett, NY 11557, USA
 E-Mail: whiterth@aol.com

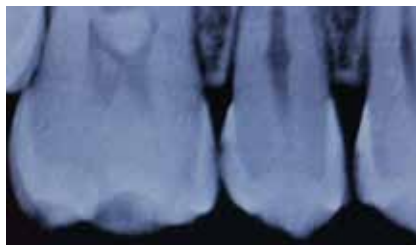


Figure 05: Radiographic examination: early onset decay in and around the contact area between the bicuspid and the molar.

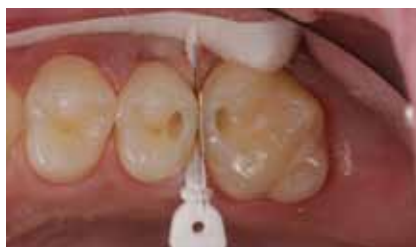

Figure 07: Tunnel preparation to access and remove the decay on both teeth.

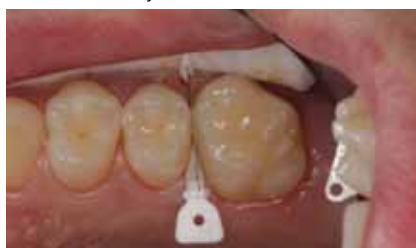

Figure 09: A highly filled esthetic flowable composite was used to fill the cavity.

References

Buonocore MG. A simple method of increasing the adhesion of acrylic filling materials to enamel surfaces. *J Dent Res* 1955; 34: 849-53

Yoshiyama M, Sano H, Carvalho RM, Pashley DH. Adhesive mechanism of a self-etching/self-priming adhesive resin to enamel and dentin. *J Hard Tiss Biol* 1996; 5: 31-5.

Fabianelli A, Vichi A, Kugel G, Ferrari M. Influence of self-etching-priming bonding systems on sealing ability of Class II restorations: leakage and SEM evaluation. Paper presented at annual meeting of the International Association for Dental Research; April 6, 2000; Washington, D.C.

Ferrari M, Goracci G, Garcia-Godoy F. Bonding mechanism of three "one-bottle" systems to conditioned and unconditioned enamel and dentin. *Am J Dent* 1997; 10: 224-30

Dr Ron Kaminer is a 1990 graduate from SUNY at Buffalo School of Dental Medicine. He maintains two practices, one in Hewlett, NY and one in Oceanside, NY. Dr Kaminer is an international expert in the field of dental lasers and has lectured on lasers and minimally invasive Dentistry nationally and internationally. He is Director of the Masters of Laser training program in New York, and is a clinical consultant and lecturer for numerous companies. He is also on the advisory board for Whiter Image and Azenic. Dr Kaminer maintains a teaching appointment at Peninsula General Hospital in Far Rockaway/NY and is also a clinical instructor with the International College of Laser Education. He has authored numerous articles on Dental lasers and minimally invasive Dentistry. He is on the editorial board of Dental Product Shopper. He is a member of the Academy of Laser Dentistry, Academy of General Dentistry, International College of Facial Esthetics, and American Dental Association.

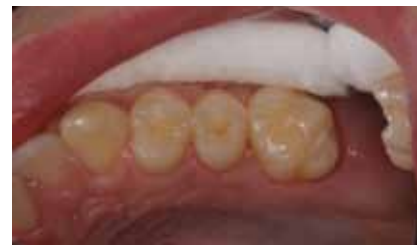

Figure 06: No occlusal break from decay.

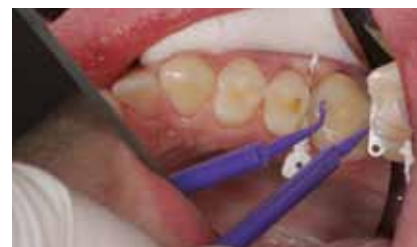

Figure 08: Futurabond U was used here in the self-etch mode.

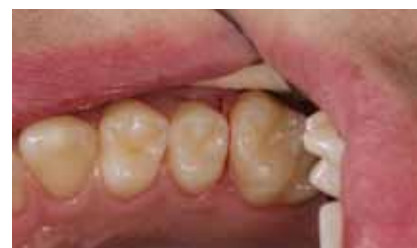

Figure 10: The final restoration.