Direct restoration of multiple teeth with the thermoviscous composite VisCalor bulk

Trifon Trifonov, ONE dental clinic

Introduction

The case presented here describes the post-endodontic (tooth #24) direct restoration of multiple teeth (teeth #24, #25 and #26) with a thermo-viscous bulk-fill nano-hybrid-composite (VisCalor bulk) which is characterised by unique advantages. The first upper left premolar had been treated endodontically for removing the odontogenic source of infection and resulted in the complete regression of the fistula that was draining pus on the vestibular mucosa between the upper premolars.

Case description

Case history

- **Reason for dental consultation**
  A 25-year-old woman presented for throbbing pain in the left maxillary region as a possible odontogenic infection.
- **Dental and Medical history**
  Her medical history was not significant for any systemic clinical condition.
  In the dental history, the patient declared a "recurrent pain with pus on the left upper jaw", which up to now could not be accurately assessed by her home physician. The dental history revealed that no root canal treatment had been performed previously in that area. Her oral hygiene consisted of "brushing my teeth everyday" and using mouthwash on the days she could not brush.
  Flossing was part of her oral hygiene regimen.

- **Patient's expectations**
  This young patient sought a clear explanation of the reason for her clinical problem and pain, and subsequent treatment.

Records and Diagnosis

- **Clinical and instrumental records**
  Combined radiological and clinical investigations showed:
  - Insufficient fillings with secondary caries on teeth #24 DO (Disto-Occlusal), #25 MOD (Mesio-Occluso-Distal) and #26 MO (Mesio-Occlusal).
  - Old direct restorations on teeth #24, #25 and #26
  - A periapical translucency that is slightly visible on the radiograph at tooth #24
  - Positive vitality test of tooth #26 and negative pulp vitality test of tooth #24
  - Sinus tract in the alveolar mucosa with release of pus between tooth #24 and #25
  - Normal tooth mobility
  - No gingival recession
  - No periodontal pocket (values of probing pocket depth were normal).

  The patient's oral hygiene care and plaque control was satisfactory.

- **Diagnosis**
  - Caries on teeth #24-#27
  - Reversible pulpitis of tooth #26 and irreversible pulp damage of tooth #24
  - Pulp necrosis and acute suppurative pulpitis draining pus in the oral cavity through a fistula between the maxilla's left upper premolars

Therapy

- **Treatment plan**
  Non-surgical Root Canal Treatment (RCT) and composite direct restorations for teeth 24, 25, 26. Tooth #27 will be followed up for possible restorative therapy as it presented a filling and initial caries.
- **Timeline of treatment steps**
  Two 90-minute appointments:
  1) RCT of tooth #24
  2) Pulp protection of the disto-occlusal cavity of tooth #26 with a suitable medication for indirect pulp capping (Calcimol, VOCO) in close proximity to the pulp under the dental filling material. The material used is a self-curing calcium hydroxide paste that supports the formation of tertiary dentine.

3) Bonding (Futurabond U, VOCO). Futurabond U is a dual-curing universal adhesive that can be used for bonding in all clinical cases, for all types of restoration and on all materials/surfaces. It is reinforced with nanoparticles for better bonding performance.
4) Build-up of the four proximal walls between teeth #24, #25 and #26 with a universal nano-filled ORMOCER-composite material (Admira Fusion, VOCO), shade A3;
5) Bulk filling of multiple teeth thanks to a thermoviscous bulk-fill nano-hybrid restorative material (VisCalor bulk, VOCO), shade A3.

Results

- **Bevor vs. After comparison**
  - Healing of the sinus tract with no symptoms
  - No radiological findings at 6 months follow-up
  - Conservative restoration of teeth #24 to #26
  - Restoration of function and aesthetics to teeth #24 to #26
  - Full patient satisfaction with shortest treatment time possible

Discussion

For rapid, long-lasting and predictable results in case of direct restoration of multiple teeth, the author required the best materials to reach this goal. During the preparation of the teeth, new undermining caries were found that also needed to be treated restoratively. The most suitable material for this treatment is the bulk-fill material VisCalor bulk (VOCO), which affords time-savings when several teeth are to be filled at the same time.

- **Rationale behind this treatment**
  - Class I and II restorations on posterior teeth
  - Base in class I and II cavities
  - Class V direct restorations
  - Locking and splinting of loose teeth
  - Repairing of veneers, enamel defects and temporary C&B-materials
  - Extended fissure sealing
  - Direct restoration of deciduous teeth in young patients
  - Core build-up
- **Special advantages of VisCalor bulk**
  Adhesive filling
- **Special advantages of the VOCO Products used**
  The very special and innovative advantage of the composite VisCalor bulk is that the material is warmed, which allows it to flow during its application before becoming sculptable immediately afterwards (thermoviscous technology).
  Additionally, VisCalor bulk has been engineered for lower shrinkage values among conventional bulk-fill composites after being heated.

Conclusion

VisCalor bulk (VOCO) is a very easy filling material to handle (comfort for the dentist), which allows short chair times (comfort for both dentist and patient), while offering excellent final results.

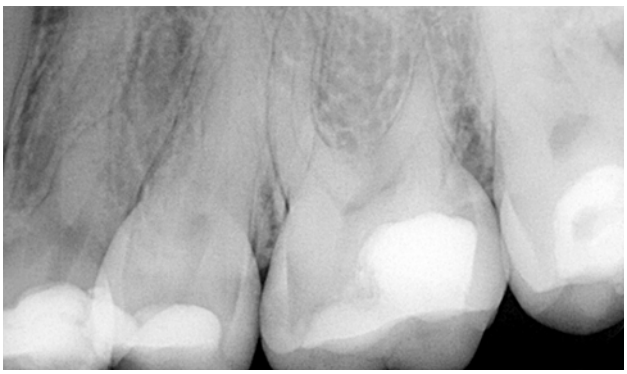

Fig. 01 Intraoral x-ray for pre-operative assessment of crown, pulp chamber, roots and peri-radicular areas reveals apical transparency at one root of tooth #24 and several fillings in-situ

Fig. 02 Intraoral x-ray for the operative assessment of working lengths for RCT (root canal treatment) of tooth #24 with rubber dam clamp in-situ.

Fig. 03 The intraoral x-ray for the post-operative assessment showed an RCT. This x-ray was used as a reference when reviewing the patient 6 to 12 months later. No signs or symptoms after 6 months.

Fig. 04 Rubber dam isolation after caries removal

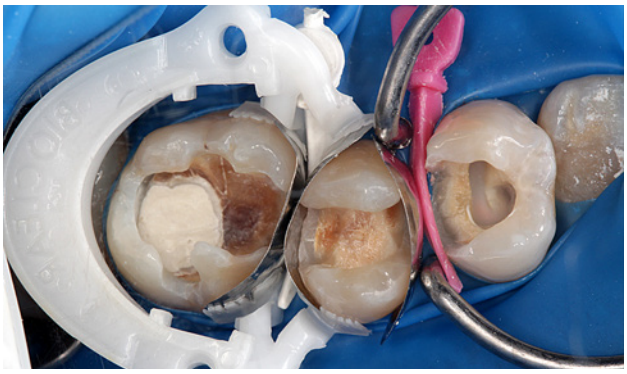

Fig. 05 Matrices in place

Fig. 06 Proximal wall build-up

Fig. 07 Finished thermoviscous bulk-fill with VisCalor bulk (VOCO)

Detailed references

Karacan AO, Ozyurt P. Effect of preheated bulk-fill composite temperature on intrapulpal temperature increase in vitro. J Esthet Restor Dent . 2019 Nov;31(6):583-588.
Barutcigil Ç, et al.. Color of bulk-fill composite resin restorative materials. J Esthet Restor Dent . 2018 Mar;30(2):E3-E8.
O'Neill C, Kreplak L, Rueggeberg FA, et al.. Effect of tooth brushing on gloss retention and surface roughness of five bulk-fill resin composites. J Esthet Restor Dent . 2018 Jan;30(1):59-69.
Algamaiah H, Sampaio CS, Rigo LC, et al.. Microcomputed Tomography Evaluation of Volumetric Shrinkage of Bulk-Fill Composites in Class II Cavities. J Esthet Restor Dent . 2017 Apr;29(2):118-127.
Behery H, et al. Cuspal Deflection of Premolars Restored with Bulk-Fill Composite Resins. J Esthet Restor Dent . Mar-Apr 2016;28(2):122-30.
Lima RBW, et al.. Depth of cure of bulk fill resin composites: A systematic Review. J Esthet Restor Dent . 2018 Nov;30(6):492-501..
Hirata R, Kabbach W, et al. Bulk Fill Composites: An Anatomic Sculpting Technique. J Esthet Restor Dent . Nov-Dec 2015;27(6):335-43.

Author

Trifon Trifonov, DDS
ONE dental clinic
t.3fonow@gmail.com